

# Spontaneous progression of experimental peri-implantitis at implants with different surface characteristics: An experimental study in dogs

Jean-Pierre Albouy, Ingemar Abrahamsson and Tord Berglundh

Department of Periodontology, The Sahlgrenska Academy, University of Gothenburg, Gothenburg, Sweden

Albouy J-P, Abrahamsson I, Berglundh T. Spontaneous progression of experimental peri-implantitis at implants with different surface characteristics. An experimental study in dogs. *J Clin Periodontol* 2012; 39: 182–187. doi: 10.1111/j.1600-051X.2011.01820.x.

## Abstract

**Aim:** To analyse spontaneous progression of ligature-induced peri-implantitis at implants with different surface characteristics.

**Material and Methods:** Four implants with similar geometry and with two different surface characteristics (turned/TiUnite; Nobel Biocare AB) were placed pairwise in one side of the mandible in five dogs, 3 months after tooth extraction. Experimental peri-implantitis was initiated by placement of ligatures and plaque formation. The ligatures were removed when about 40% of the supporting bone was lost. After 6 months, block biopsies were obtained and prepared for histological analysis.

**Results:** The amount of bone loss that occurred during the plaque accumulation period after ligature removal was significantly larger at implants with a TiUnite surface than at implants with a turned surface. The histological analysis revealed that the vertical dimensions of the lesion and the pocket epithelium and the apical extension of the biofilm were significantly larger at TiUnite implants than at turned implants.

**Conclusion:** It is suggested that the implant surface characteristics influence progression of peri-implantitis.

Key words: animal experiment; bone level; dental implants; infection; inflammatory lesion; peri-implantitis; titanium

Accepted for publication 17 October 2011

Peri-implantitis is an infectious disease characterized by crestal bone loss and bleeding on probing with or without deepening of peri-implant

pockets (Lang & Berglundh 2011). The inflammatory lesions associated with peri-implantitis are often circumferential in nature and exhibit several histopathological differences to periodontitis lesions around teeth (Berglundh et al. 2011). Experimental models in animals have been used to produce periodontitis and peri-implantitis lesions. Although the process of ligature-induced breakdown may not resemble natural disease progression, the resulting lesions in

such models have many features in common with those analysed from human biopsy material. Peri-implantitis lesions, in contrast to lesions in periodontitis at teeth, extended apical of the pocket epithelium, were in the apical portion in direct contact with biofilm in the pocket and often reached the bone crest (Berglundh et al. (2011).

In the experimental models, the ligatures were removed several weeks before biopsy and analysis. Marinello

## Conflict of interest and source of funding statement

The authors have no conflict of interest. This study was supported by grants from the Swedish Dental Society and TUA research, Gothenburg, Sweden.

et al. (1995), in a study on experimental peri-implantitis in Labrador dogs, reported that in sites where biopsies were obtained at 1 month after ligature removal, the inflammatory lesions extended to the bone crest. In biopsies collected 3 months after ligature removal, however, the lesions either continued to progress with additional bone loss or became encapsulated and separated from the bone crest. The finding that experimental peri-implantitis lesions could progress also after the removal of ligatures was challenged in an experimental study in dogs by Zitzmann et al. (2004). They performed ligature-induced breakdown around implants in Labrador dogs and analysed tissue reactions 12 months after ligature removal. Although the majority of sites (16 of 21) exhibited disease progression with extensive inflammatory lesions in the connective tissue and additional bone loss, few sites demonstrated encapsulation of the lesions and no further breakdown of peri-implant bone occurred. As the disease progressed after the removal of ligatures, Zitzmann et al. (2004) suggested that the observations in the study described spontaneous progression of experimental peri-implantitis.

The experimental model presented by Zitzmann et al. (2004) was subsequently used in studies on spontaneous progression of experimental peri-implantitis around implants with different surface roughness. Berglundh et al. (2007) evaluated tissue reactions following ligature removal around implants with custom-made smooth and rough surfaces. It was reported that spontaneous progression of experimental peri-implantitis was more pronounced around implants with a rough surface than around implants with a smooth surface. Albouy et al. (2008, 2009) performed a similar experiment using commercially available implants and reported that spontaneous progression of peri-implantitis occurred around all four types of implants and was more pronounced at implants with a TiUnite surface.

The question on how implant surface characteristics influence peri-implant disease was addressed in a review by Renvert et al. (2011). It was concluded that only few studies provided data in this field and that,

based on the limited data, there is no evidence that implant surface characteristics had a significant influence on the initiation of peri-implantitis. It was also stated that there is limited information from experimental studies suggesting that implant surface characteristics influence progression of established peri-implantitis.

The experimental study by Albouy et al. (2008, 2009) included implants that differed both in geometry and surface characteristics. To elucidate the question on how implants surface characteristics influence progression of peri-implantitis, the experimental model of spontaneous progression of experimentally induced peri-implantitis was applied to implants with similar geometry. The aim of the present study was to analyse spontaneous progression of ligature-induced peri-implantitis at implants with different surface characteristics.

## Material and Methods

### Animals

The regional Ethics Committee for Animal Research, Göteborg, Sweden, approved the study protocol. Six Labrador dogs, about 1 year old, were used. The outline of the experiment is presented in Fig. 1. During all surgical procedures, general

anaesthesia was induced with intravenously injected Propofol (10 mg/ml, 0.6 ml/kg) and sustained with N<sub>2</sub>O:O<sub>2</sub> (1:1.5–2) and Isoflurane employing endo-tracheal intubation.

### Surgery

The three anterior pre-molars in one side of the mandible and the maxilla were extracted in all dogs. After 3 months, mucoperiosteal flaps were elevated. Four implants with similar geometry and with two different surface characteristics (implant group A and B; Table 1) were placed pairwise in a randomized order. All implants were provided with healing abutments. The flaps were adjusted and sutured around the neck of the implants.

Radiographs were obtained for each implant site using a customized film holder (KerrHawe, Bioggio, Switzerland) as previously described by Persson et al. (1999) and Albouy et al. (2008, 2009). The radiographs were analysed using an Olympus SZH10 stereo microscope (Olympus; Tokyo, Japan) and digital images obtained with a Leica DFC280 camera (Leica; Wetzlar, Germany). The abutment fixture junction was used as a reference landmark for all radiographic measurements. The vertical distance between the reference

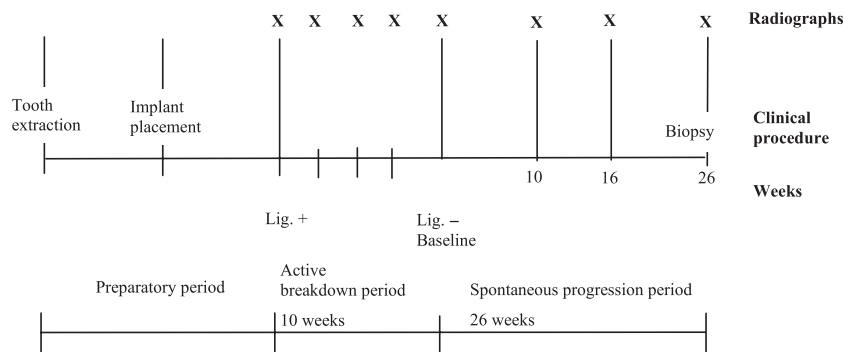


Fig. 1. Outline of the study: Ligatures were placed 3 months after implant installation (Lig.+) and removed 12 weeks later (Baseline, Lig.-). Radiographs (X) were obtained at baseline, week 10, 16 and 26.

Table 1. Characteristics of implant types

Implant group	Surface	Name	Dimensions	Company
A	Turned	MKIII Narrow Platform	3.3 × 10 mm	Nobel Biocare AB, Göteborg, Sweden
B	TiUnite	MKIII Narrow Platform	3.3 × 10 mm	Nobel Biocare AB, Göteborg, Sweden

landmark and the marginal bone level was assessed at the mesial and distal aspects of each implant using the QWin software (Leica Qwin Standard V3.2.0, Leica Imaging Systems Ltd., Cambridge, UK). Double assessments were made by two examiners with a 2-month interval.

The examiners were blinded with regard to the group identity of the implants for all measurements.

The sutures were removed after 2 weeks, and a plaque control programme including daily cleaning of implants and teeth was initiated.

#### Experimental peri-implantitis

Three months after implant installation, experimental peri-implantitis was initiated. Thus, oral hygiene procedures were abandoned, and cotton ligatures were placed in a sub-marginal position around the neck portion of all implants (Fig. 1) (Lindhe et al. 1992). A new set of radiographs was obtained. The ligatures were replaced every third week. The progression of bone loss was monitored in radiographs. The ligatures were removed 10 weeks after the commencement of the ligature breakdown period and when about 40% of the supporting bone was lost. Plaque accumulation continued during the subsequent 26-week period.

Radiographic and clinical examinations were performed at baseline (lig.), at 10, 16 and 26 weeks after ligature removal (Fig. 1).

#### Histological preparation and analysis

At week 26, the dogs were euthanized with a lethal dose of Sodium-Pentothal® (Hospira Enterprises B. V., Hoofddorp, the Netherlands) and perfused through the carotid arteries with 4% formaldehyde. The mandibles were retrieved and stored in the fixative. The mandibles were removed, and tissue blocks containing the implant and the surrounding soft and hard tissues were dissected using a diamond saw (Exakts, Kulzer, Germany) and processed for ground sectioning according to the methods described by Donath & Breuner (1982). Each block was cut in a bucco-lingual plane using a cutting-grinding unit (Exakts, Apparatebau, Norderstedt, Germany). From each implant site, two central

sections (buccal-lingual plane) were obtained and further reduced to a final thickness of about 20 µm using a micro-grinding unit (Exakts, Apparatebau). The remaining mesial and distal portions were re-mounted and cut in a perpendicular (mesio-distal) direction and two central sections were prepared from each unit. The sections were stained in toluidine blue or fibrin stain of Ladewig (Donath & Breuner 1982).

The histological examinations were performed using a Leica DM-RBE microscope (Leica, Heidelberg, Germany) equipped with an image system (Q-500 MC, Leica). The following landmarks were identified and used for the linear measurement. The marginal position of the peri-implant mucosa (PM), the abutment-fixature (A/F) junction, the apical termination of the plaque/biofilm on the implant surface (aPlaque), the apical termination of the pocket epithelium (aPE), the marginal position of bone-to-implant contact (BIC), the coronal and apical extension of the infiltrated connective tissue (cICT and aICT). The surface areas of the ICT (area ICT) in the connective tissue, the biofilm (Biofilm area) in the pocket compartment and the hard tissue defect (Defect area) were evaluated by outlining their circumferences with a cursor.

#### Data analysis

Mean values for all variables were calculated for each implant in each

animal. Differences were analysed between implant types using the Student's *t*-test for paired samples ( $n = 5$ ). The null hypothesis was rejected at  $p < 0.05$ .

#### Results

Healing after implant placement was uneventful at all implant sites. One dog developed Addison's disease and was euthanized 2 months after implant installation. Plaque formation during experimental peri-implantitis resulted in overt signs of inflammation in the mucosa around all implants. Signs of inflammation in the peri-implant mucosa and gross amounts of plaque on the implants persisted during the period after ligature removal.

#### Radiographic findings

The amount of bone loss that occurred during the preparatory phase of ligature-induced breakdown was  $3.00 \pm 0.44$  mm at implants of group A and  $3.27 \pm 0.45$  mm at implants of group B. Radiographs from the different implant sites at ligature removal (baseline) and at biopsy are presented in Fig. 2. The mean bone loss that took place during the period between ligature removal and biopsy (26 weeks) was  $0.03 \pm 0.50$  mm for implants in group A and  $1.47 \pm 0.65$  mm for implants in group B (Fig. 3 and Table 2). This difference was statistically significant. Bone level altera-

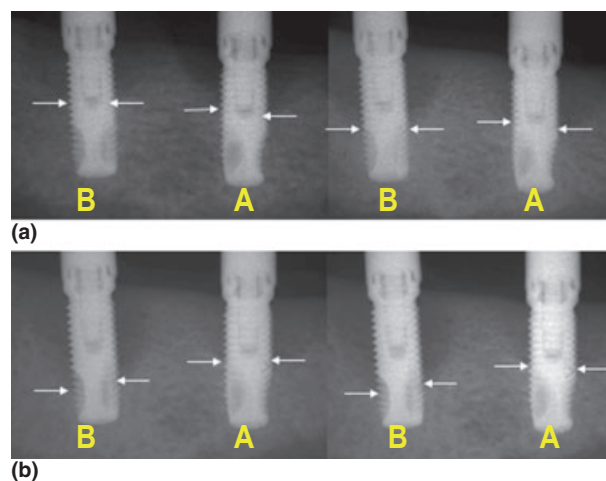


Fig. 2. Radiographs from implant types A and B (from left) obtained at ligature removal (baseline) (a) and at biopsy (26 weeks) (b). Arrows indicate bone levels.

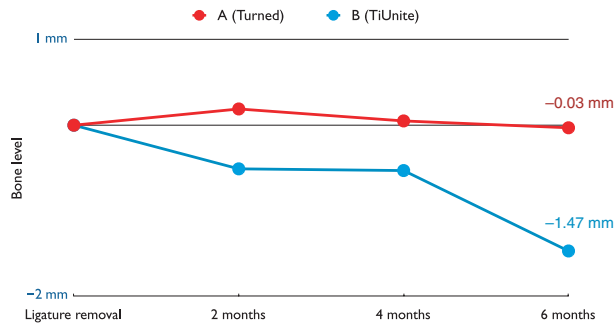


Fig. 3. Bone level alterations during the period following ligature removal.

Table 2. Results from the radiographic measurements. Bone level alterations (mm) during the 26-week period following ligature removal (Baseline-26w). Mean values and standard deviations (SD) ( $n = 5$ )

Bone level alterations (mm)	Implant A turned	Implant B TiUnite
Baseline (ligature removal) – 6 months	0.03 (0.50)*	1.47 (0.65)

\* $p$ -value < 0.05.

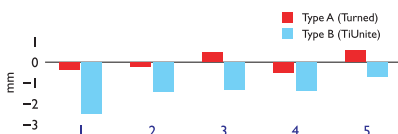


Fig. 4. Histogram illustrating bone level alterations following ligature removal for each animal (1–5).

tions for the two implant types within each animal are illustrated in Fig. 4. The results from the reproducibility assessments revealed a standard deviation (SD) of 0.04 for examiner 1 and 0.32 mm for examiner 2. The inter-examiner SD was 0.24 mm.

#### Histological findings

Bucco-lingual sections representing the two implant types are presented in Fig. 5. Extensive osseous defects were associated with large inflammatory cell infiltrates in the connective tissue around all implants. An ulcerated pocket epithelium lined the inflamed part of the mucosa towards the pocket compartment. This epithelium terminated at a varying distance apical of the mucosal margin, and the apical portion of the inflammatory lesion was thereby left uncovered and in direct contact with the biofilm on the implant surface. Biofilm formation was more conspicuous at implants of group B than at implants of group A.

The results from the histometric measurements are reported in Table 3. The assessments on dimensions and areas revealed overall larger mean values for specimens representing implants of group B than those of group A. Thus, the distance between the margin of the peri-implant mucosa and the apical position of the pocket epithelium (PM-aPE) was significantly longer at type B than type A implants ( $5.06 \pm 1.56$  mm versus  $3.23 \pm 0.77$  mm). The distance between PM and the first bone-to-implant contact (BIC) was  $4.69 \pm 0.98$  mm and  $6.04 \pm 1.74$  mm for type A and B implants respectively. The apical extension of the biofilm (aPlaque) in relation to A/F was  $1.92 \pm 1.14$  mm at implants of type A and  $3.71 \pm 1.39$  mm at implants of type B. This difference was statistically significant. The distance between A/F and BIC varied between  $4.38 \pm 0.67$  mm (A) and  $4.93 \pm 1.41$  mm (B). The vertical dimension of the ICT (aICT-eICT) was significantly larger at implants type B than at implants type A ( $4.92 \pm 1.81$  mm versus  $3.05 \pm 1.02$  mm).

Although the ICT area varied between  $2.29 \pm 2.14$  mm<sup>2</sup> (implant A) and  $3.62 \pm 2.87$  mm<sup>2</sup> (implant B), the biofilm occupied a considerably smaller compartment with the pocket area at both type A and type B implants ( $0.06 \pm 0.07$  and  $0.46 \pm 0.45$  mm<sup>2</sup>). The assessment of the dimensions of the hard tissue defect revealed areas

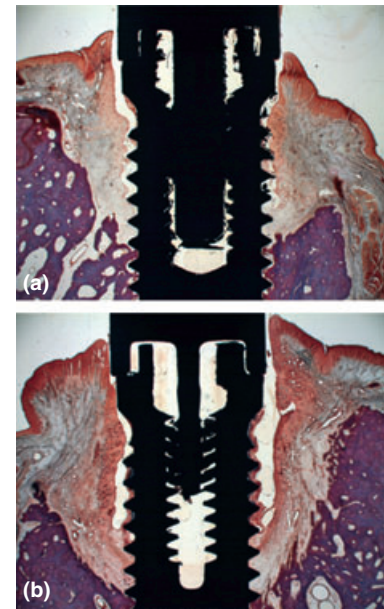


Fig. 5. Buccal-lingual sections from implant groups A (a) and B (b). Fibrin stain of Ladewig.

of  $2.22 \pm 1.55$  mm<sup>2</sup> (type A) and  $3.81 \pm 2.28$  mm<sup>2</sup> (type B).

#### Discussion

In the present study, spontaneous progression of ligature-induced peri-implantitis at implants with different surface characteristics was analysed. It was demonstrated that the amount of bone loss that occurred during the plaque accumulation period after ligature removal was significantly larger at implants with a TiUnite surface than at implants with a turned surface. The histological analysis revealed that the vertical dimensions of the ICT and the pocket epithelium and the apical extension of the biofilm were significantly larger at TiUnite implants than at turned implants. It is suggested that implant surface characteristics influence progression of peri-implantitis.

The effect of implant surface characteristics on spontaneous progression of experimental peri-implantitis was previously analysed in our laboratory. Thus, Berglundh et al. (2007) in a study in dogs evaluated tissue reactions following ligature removal at implants with smooth, polished or rough surfaces, and SLA surfaces exposed to experimental peri-implantitis. It was reported that spontaneous progression was more

Table 3. Results from the histometric measurements at the two implant types; Mean values and standard deviations (SD) ( $n = 5$ )

Dimensions (mm), areas (mm <sup>2</sup> )	Implant A turned	Implant B TiUnite
Pm-aPE	3.23 (0.77)*	5.06 (1.56)
Pm-BIC	4.69 (0.98)	6.04 (1.74)
AF-aPlaque	1.92 (1.14)*	3.71 (1.39)
AF-BIC	4.38 (0.67)	4.93 (1.41)
aICT-cICT	3.05 (1.02)*	4.92 (1.81)
Area ICT (mm <sup>2</sup> )	2.29 (2.14)	3.62 (2.87)
Biofilm area (mm <sup>2</sup> )	0.06 (0.07)	0.46 (0.45)
Defect area (mm <sup>2</sup> )	2.22 (1.55)	3.81 (2.28)

\* $p$ -value < 0.05.

The marginal position of the peri-implant mucosa (PM), the abutment–fixture (A/F) junction, the apical termination of the plaque/biofilm on the implant surface (aPlaque), the apical termination of the pocket epithelium (aPE), the marginal position of bone-to-implant contact (BIC), the coronal and apical extension of the infiltrated connective tissue (cICT and aICT).

pronounced at the implants with the rough surface than those with a smooth surface. Although the surface of the implants in the study by Berglundh et al. (2007) was custom made, a subsequent experimental study using commercially available implants was performed. Albouy et al. (2008, 2009) in a study in dogs applied the spontaneous progression model on experimental peri-implantitis around implants with turned, TiOblast, SLA and TiUnite surfaces. It was reported that spontaneous progression occurred around all implant types during the 6-month period after ligature removal and that progression was most pronounced at the TiUnite implants. The difference in bone loss following ligature removal between the implants with turned surfaces and implant with TiUnite surfaces in the study by Albouy et al. 2008 was 0.94 mm. The corresponding comparison made in the present study yielded a difference of 1.44 mm. This observation underlines again that surface characteristics of the implant influence progression of peri-implantitis when using the current experimental model. A further analysis of the results related to the amount of bone loss after the removal of ligatures in the present study revealed that the values representing the two implant types were smaller than those reported in the study by Albouy et al. (2008). Thus, spontaneous progression of experimental peri-implantitis during 6 months after ligature removal around implants with turned surfaces measured 1.84 mm in the study by Albouy et al. (2008), whereas the corresponding assess-

ment in current study amounted to 0.03 mm. For the TiUnite surface implants, the ensuing results were 2.78 mm in the study by Albouy et al. (2008) and 1.47 mm in the present experiment. The difference in the amount of additional bone loss after ligature removal between the two studies may be related to differences in the overall host response in the two groups of animals. The consistent difference in bone loss between implant types in the two studies, however, emphasizes the validation of such a finding.

Martins et al. (2005) in a study in dogs reported on tissue reactions after ligature removal in experimental peri-implantitis around implants with either HA coating, TPS, turned or acid etched surfaces. During the 12-month period after ligature removal, the implants were exposed to daily scrubbing with 0.12% chlorhexidine. Despite the cleaning procedures after ligature removal, 17 of the 36 implants were lost because of continuous bone loss during the follow-up period. The lost implants in the study by Martins et al. (2005) represented all four surface types. Although Martins et al. (2005) applied oral hygiene procedures during the period after ligature removal and thereby presented a different experimental outline than that of the present study and previous experiments from our laboratory, the findings of additional bone loss after ligature removal were consistent.

The histological analysis in the present study revealed that the tissues around TiUnite implants had larger vertical dimensions of pocket

epithelium and connective tissue lesion and a further apical extension of the biofilm than tissues around turned implants. This finding indicates that the difference in surface characteristics between the two implant types had a significant influence on variables expressing pathology. Similar observations were made by Berglundh et al. (2007) in a study on spontaneous progression of experimental peri-implantitis in dogs. It was reported that the size of the inflammatory lesions in the connective tissue and the biofilm area in the pocket compartment were larger in biopsies prepared from sites around implants with a rough surface than in those representing smooth surface implants. In this context, it should be pointed out that the implants used in the study by Berglundh et al. (2007) were custom made and exhibited large differences in surface roughness as expressed in Sa-values (Wennerberg & Albrektsson 2009). Despite the fact that the corresponding difference in surface roughness between the two types of implants in the present study was considerably smaller than those used in the study by Berglundh et al. (2007), the current findings on more pronounced progression of bone loss and larger inflammatory lesions around TiUnite implants than turned implants indicate that surface characteristics other than roughness influence the risk for progression of peri-implant disease.

In the study by Albouy et al. (2009) on spontaneous progression of experimental peri-implantitis around implants with turned, TiOblast, SLA and TiUnite surfaces, it was reported that all sites exhibited large inflammatory cell infiltrates and that pus, biofilm and calculus were found in the pocket areas. The largest values describing size and vertical extension of the ICT were found for implants with the TiUnite surface in relation to the three other implant types. Also, this finding is in agreement with observations made in the present study.

## References

- Albouy, J.-P., Abrahamsson, I., Persson, L. G. & Berglundh, T. (2008) Spontaneous progression of peri-implantitis at different types of implants. An experimental study in dogs. I:

- clinical and radiographic observations. *Clinical Oral Implants Research* **19**, 997–1002.
- Albouy, J.-P., Abrahamsson, I., Persson, L. G. & Berglundh, T. (2009) Spontaneous progression of ligature induced peri-implantitis at implants with different surface characteristics. An experimental study in dogs II: histological observations. *Clinical Oral Implants Research* **20**, 366–371.
- Berglundh, T., Abrahamsson, I., Welander, M., Lang, N. P. & Lindhe, J. (2007) Morphogenesis of the peri-implant mucosa: an experimental study in dogs. *Clinical Oral Implants Research* **18**, 1–8.
- Berglundh, T., Zitzmann, N. U. & Donati, M. (2011) Are peri-implantitis lesions different from periodontitis lesions? *Journal of Clinical Periodontology* **38**(Suppl. 11), 188–202.
- Donath, K. & Breuner, G. (1982) A method for the study of undecalcified bones and teeth with attached soft tissues. The Sage-Schliff (sawing and grinding) technique. *Journal of Oral Pathology* **11**, 318–326.
- Lang, N. P. & Berglundh, T. (2011) Periimplant diseases: where are we now? – consensus of the seventh European workshop on periodontology. *Journal of Clinical Periodontology* **38**(Suppl. 11), 178–181.
- Lindhe, J., Berglundh, T., Ericsson, I., Liljenberg, B. & Marinello, C. (1992) Experimental breakdown of peri-implant and periodontal tissues. A study in the beagle dog. *Clinical Oral Implants Research* **3**, 9–16.
- Marinello, C., Berglundh, T., Ericsson, I., Klinge, B., Glantz, P. & Lindhe, J. (1995) Resolution of ligature-induced peri-implantitis lesions in the dog. *Journal of Clinical Periodontology* **22**, 475–479.
- Martins, M. C., Shibli, J. A., Abi-Rached, R. S. G. & Marcantonio, E. (2005) Progression of experimental chronic peri-implantitis in dogs: clinical and radiographic evaluation. *Journal of Periodontology* **76**, 1367–1373.
- Persson, L. G., Araujo, M. G., Berglundh, T., Grondahl, K. & Lindhe, J. (1999) Resolution of peri-implantitis following treatment. An experimental study in the dog. *Clinical Oral Implants Research* **10**, 195–203.
- Renvert, S., Polyzois, I. & Claffey, N. (2011) How do implant surface characteristics influence peri-implant disease? *Journal of Clinical Periodontology* **38**(Suppl. 11), 214–222.
- Wennerberg, A. & Albrektsson, T. (2009) Effects of titanium surface topography on bone integration: a systematic review. *Clinical Oral Implants Research* **20**(Suppl. 4), 172–184.
- Zitzmann, N. U., Berglundh, T., Ericsson, I. & Lindhe, J. (2004) Spontaneous progression of experimentally induced periimplantitis. *Journal of Clinical Periodontology* **31**, 845–849.

Address:  
 T. Berglundh  
 Department of Periodontology  
 The Sahlgrenska Academy  
 University of Gothenburg  
 Box 450  
 SE 405 30 Göteborg  
 Sweden  
 E-mail: [tord.berglundh@odontologi.gu.se](mailto:tord.berglundh@odontologi.gu.se)

### Clinical Relevance

*Scientific rationale for the study:* There is limited information on how implant surface characteristics influence progression on peri-implantitis.

*Principal findings:* Radiographic bone loss was more pronounced at implants with a TiUnite surface

than at implants with a turned surface after ligature removal. The vertical dimensions of the inflammatory lesion and the pocket epithelium and the apical extension of the biofilm were significantly larger at TiUnite implants than at turned implants.

*Practical implications:* The finding that spontaneous progression of

peri-implantitis was more pronounced at implants with a specific surface modification points to the need of analysing risks with such modifications in relation to peri-implant diseases. Clinical studies on large subject samples representing different implant types are needed.